



ISSN 1989 – 9572

DOI: 10.47750/jett.2022.13.06.077

# Awareness On The Management Of Iatrogenic Arterial Nicking During Dental Surgical Procedures Among Dental Students.

Akshaya. K<sup>1</sup>

Kiran Kumar Pandurangan<sup>2</sup>

Nabeel Ahmed<sup>3\*</sup>

Dhanraj Ganapathy<sup>4</sup>

Subhabrata Maiti<sup>5</sup>

Journal for Educators, Teachers and Trainers, Vol. 13 (6)

<https://jett.labosfor.com/>

Date of reception: 20 Oct 2022

Date of revision: 18 Nov 2022

Date of acceptance: 12 Dec 2022

**Akshaya. K, Kiran Kumar Pandurangan, Nabeel Ahmed, Dhanraj Ganapathy, Subhabrata Maiti (2022). Awareness On The Management Of Iatrogenic Arterial Nicking During Dental Surgical Procedures Among Dental Students .*Journal for Educators, Teachers and Trainers*, Vol. 13(6). 779-790.**

---

<sup>1</sup>Graduate student, Department of prosthodontics, Saveetha Dental College and Hospitals, Saveetha Institute of Medical and Technical Sciences, Saveetha University, 162, P.H. Road, Tamil Nadu, India. Chennai-600077.

<sup>2</sup>Reader, Department of Prosthodontics, Saveetha Dental College and Hospitals, Saveetha Institute of Medical and Technical Sciences, Saveetha University, 162, P.H. Road, Tamil Nadu, India. Chennai-600077.

<sup>3</sup>Assistant professor, Department of Prosthodontics, Saveetha Dental College and Hospitals, Saveetha Institute of Medical and Technical Sciences, Saveetha University, 162, P.H. Road, Tamil Nadu, India. Chennai-600077.

<sup>4</sup>Professor and Head, Department of Prosthodontics, Saveetha Dental College and Hospitals, Saveetha Institute of Medical and Technical Sciences, Saveetha University, 162, P.H. Road, Tamil Nadu, India. Chennai-600077.

<sup>5</sup>Assistant professor, Department of Prosthodontics, Saveetha Dental College and Hospitals, Saveetha Institute of Medical and Technical Sciences, Saveetha University, 162, P.H. Road, Tamil Nadu, India. Chennai-600077.



## **Awareness On The Management Of Iatrogenic Arterial Nicking During Dental Surgical Procedures Among Dental Students.**

**Akshaya. K<sup>1</sup>, Kiran Kumar Pandurangan<sup>2</sup>, Nabeel Ahmed<sup>3\*</sup>, Dhanraj Ganapathy<sup>4</sup>, Subhabrata Maiti<sup>5</sup>**

<sup>1</sup>Graduate student, Department of prosthodontics, Saveetha Dental College and Hospitals, Saveetha Institute of Medical and Technical Sciences, Saveetha University, 162, P.H. Road, Tamil Nadu, India. Chennai-600077.

<sup>2</sup>Reader, Department of Prosthodontics, Saveetha Dental College and Hospitals, Saveetha Institute of Medical and Technical Sciences, Saveetha University, 162, P.H. Road, Tamil Nadu, India. Chennai-600077.

<sup>3</sup>Assistant professor, Department of Prosthodontics, Saveetha Dental College and Hospitals, Saveetha Institute of Medical and Technical Sciences, Saveetha University, 162, P.H. Road, Tamil Nadu, India. Chennai-600077.

<sup>4</sup>Professor and Head, Department of Prosthodontics, Saveetha Dental College and Hospitals, Saveetha Institute of Medical and Technical Sciences, Saveetha University, 162, P.H. Road, Tamil Nadu, India. Chennai-600077.

<sup>5</sup>Assistant professor, Department of Prosthodontics, Saveetha Dental College and Hospitals, Saveetha Institute of Medical and Technical Sciences, Saveetha University, 162, P.H. Road, Tamil Nadu, India. Chennai-600077.

\*Corresponding Author

Email : 151701075.sdc@saveetha.com<sup>1</sup>, kirankumar.sdc@saveetha.com<sup>2</sup>, nabeeln.sdc@saveetha.com<sup>3</sup>, dhanraj@saveetha.com<sup>4</sup>, subhabratamaiti.sdc@saveetha.com<sup>5</sup>

### **ABSTRACT**

**Background:** Bleeding during surgery may be a serious clinical problem which will be very disconcerting to the patient and will have serious consequences. During the course of nearly all kinds of surgery, blood vessels are going to be disrupted, causing some bleeding. The dentist should be aware of all techniques of hemorrhage control for various sorts of bleeding episodes – small vessels, large vessels, oozing, drug-induced, or when an underlying coagulation defect is present. Bleeding complications can occur in healthy also as systemically compromised patients.

**Aim:** The aim of the current study is to analyse the awareness and knowledge on the management of iatrogenic arterial nicking among dental undergraduate students.

**Materials and Methods:** The study was a cross-sectional questionnaire study. Survey was designed as a questionnaire in English with 2 sections. Section 1 contained demographics and section 2 had questions on various techniques on management of arterial injury, which was answered by 150 dental undergraduate students. All the obtained data were entered on Microsoft excel sheet and analysed using SPSS by IBM.

**Results:** From the statistical analysis it is clear that almost 75% of the respondents from final year and internship were aware of different methods of management and prevention of dental injuries, yet only minimal number of students from other three years were aware of the methods and procedures to be followed at each step during dental surgical procedures,

**Conclusion:** Within the limitations of the current study, it can be concluded that the majority of dental undergraduate students are aware of different methods of presentation and management of iatrogenic arterial nicking during dental surgical procedures. In the present study the knowledge on the methods of management such as mobilisation, deep sutures, burnishing of bone, use of bone grafting was lacking among first to third year students when compared to students pursuing their final year and internship

**Keywords:** Arterial Nicking; Hematoma; Iatrogenic; Innovative; Surgical procedures

### **INTRODUCTION**

Haemorrhage means the escape of blood from a vessel. Haemorrhage generally indicates extravasation of blood because of vessel rupture. Blood carries oxygen and nutrients to the tissues and is significant for body functions. Loss of blood because of any reason beyond a particular point is potentially life threatening and will result in loss of life. (1,2) The unintentional nicking of the blood vessels (artery or vein) with needle during the injection of local anaesthesia might lead to effusion of blood into the extravascular spaces with subsequent hematoma formation. (3) Puncture of vein by needle may or might not result in the formation of hematoma but perforation of arteries subsequently develop hematoma which rapidly increases in size until treatment is instituted because

of significantly greater pressure level within the artery. The size of the hematoma also depends upon the density of the tissues surrounding the vessel. (4,5)

The swelling and discoloration of the involved region usually subsides in 10–15 days. The patient may additionally experience soreness and trismus. The patient should be advised to take analgesic, avoid any heat application which could increase the size of the hematoma because of vasodilatation, application of ice immediately after developing hematoma helps in minimizing the size by vasoconstriction and even have palliative effect. Ice packs half-hour per hour for the first 24 hours after surgery following which intermittent hot moist packs are often accustomed to resolve the condition.(4,6) Any dental treatment in the involved region should be avoided until symptoms and signs resolve. Hematoma places pressure on tissues / wounds, decreases vascularity and increases tension on the injuries edges and also acts as culture media potentiating the event of a wound infection so antibiotic therapy should be prescribed if the hematoma is large. To prevent formation of hematoma during any nerve block, thorough knowledge of normal anatomy of that specific region is extremely important. The injection techniques are often modified as dictated by the patient's anatomy. The chance of hematoma formation during posterior superior nerve block is highest followed by the inferior alveolar nerve and mental/incisive nerve block. To attenuate the chance of hematoma formation, use of a short needle and minimum number of needle penetration into tissues should be considered.(7)

Trigeminal nerve injury is one of the most problematic consequences of dental surgical procedures with major medico-legal implications.(8) The incidence of lingual nerve injury has remained static within the UK over the last 30 years. However, the incidence of inferior alveolar nerve injury has increased, this being because of implant surgery and endodontic therapy.(9) Iatrogenic injuries to the third division of the trigeminal remain a standard and complicated clinical problem(10). Altered sensation and pain in the orofacial region may interfere with speaking, eating, toothbrushing and drinking. Usually after oral rehabilitation, the patient expects and experiences significant improvements, not only regarding jaw function, but also in reference to dental, facial, and even overall body image. Thus these injuries have a big negative effect on the patient's quality of life and therefore the iatrogenesis of those injuries cause significant psychological effects.(11,12)

The incidence of implant-related inferior alveolar nerve (IAN) nerve injuries vary from 0–40%.(13) Of edentulous patients, 25% present with a degree of altered IAN function, thus reinforcing the rules on the need of pre-operative neurosensory evaluation. Great care must be taken when selecting the patient and possible sites for implant placement. Appropriate radiographic evaluation of the implant site is indicated.(14) Harris et al (15) have reported explicit recommendations for pre-operative radiographic evaluation before placement of implants. Cone beam CT scanning, now introduced to several specialist practices and dental hospitals, will provide low radiation dosage and improved imaging for planning implant treatment. If there's an inferior alveolar arterial or venous bleed, it's going to be advisable to not place the implant and to attend 2–3 days to ensure no nerve damage has occurred then place the implant in granulation tissue, which shouldn't compromise the success of the implant.(16) However, there is no evidence to support this practice yet. If a nerve injury is suspected, the clinician should perform a basic neurosensory examination of the neuropathic area and ascertain whether the patient experiences pain, altered sensation or numbness and document the results within the day of surgery (when the consequences of the anaesthetic should have worn off ). An easy phone Call 6 hours post surgery will enable the surgeon to determine from the patient whether the analgesic effects of the local analgesia have worn off and if neuropathy is present.(17) Our team has extensive knowledge and research experience that has translated into high quality publications(18,19),(20–22),(23–38)

.In this research we are studying and analyzing the knowledge on the management of iatrogenic arterial nicking during dental surgical procedures among dental undergraduate students.

## **MATERIALS AND METHODS**

The present study was a cross sectional questionnaire study that was carried out to assess the knowledge on the management of iatrogenic arterial nicking during dental surgical procedures among dental undergraduate students. A total of 150 subjects participated in the study of 30 students from each year of study, I year till internship. The survey period extended for a period of 20 days in April 2019. The study involved completion of a predesigned questionnaire that had questions on Causes of bleeding during implant placement, the length of implant that can cause perforation, methods on prevention of iatrogenic nicking of arteries and questions related to the management of the same. The study subjects consisted of undergraduate dental students of all years. Dental students from 1st year till CRRI available at the time of study were included in the study while students pursuing other courses were excluded from the study.

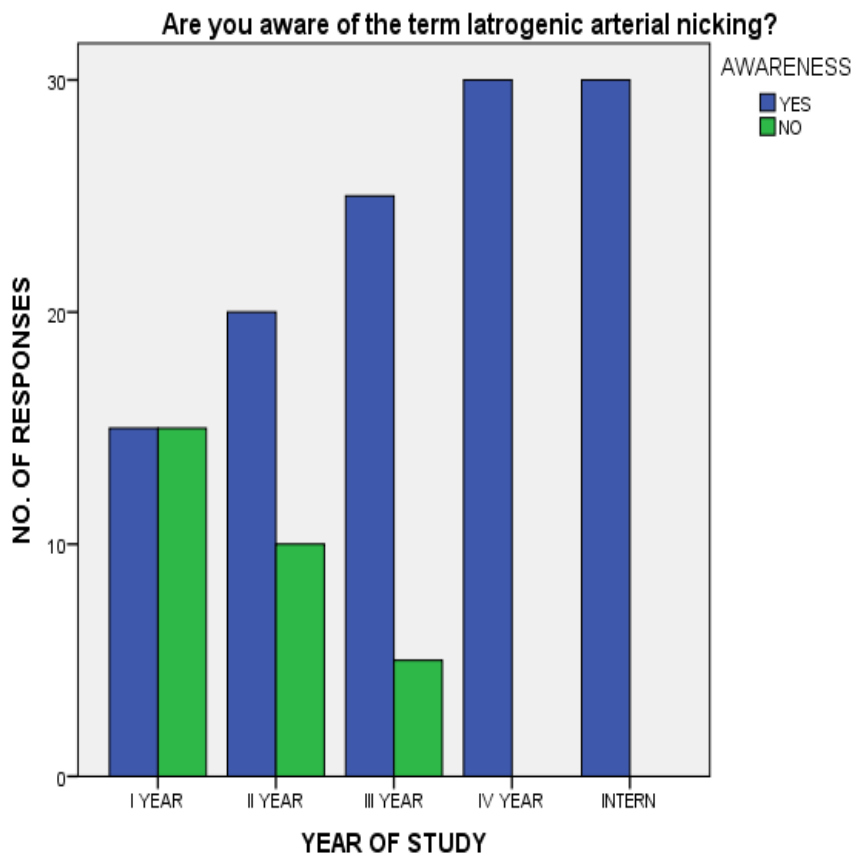
### **Structure of the questionnaire**

The study involved completion of a predesigned questionnaire containing 2 sections. Section I includes demographic characteristics like age, gender, course and year of study of the participants. Section two had questions on prevention, causes and management of iatrogenic arterial nicking in dental surgical procedures. 13 questionnaires, which had been designed based on the primary objective of the study, were used. The

questionnaire was prepared in English . The participants were asked to put the responses in a questionnaire. The Data was Shortlisted according to the year of study, data recorded in excel and was subjected to statistical analysis in SPSS by IBM.

**RESULTS AND DISCUSSIONS**

From the statistical analysis, it is evident that most of the interns and final year dental undergraduate students had a decent knowledge on management of iatrogenic arterial nicking during oral surgical procedures when compared to students of other years. Only 50% of the students from I year were aware of the term iatrogenic arterial nicking, while 100% of students from final year and internship were aware of the term iatrogenic arterial nicking (Figure 1). With regard to the cause of bleeding during implant placement in the mandibular region, the maximum number of students from final year (80%) and internship (90%) have answered correctly to be due to perforation of lingual plate and Damage of sublingual artery (Figure 2). 100% of students from internship were aware of the fact that implants of length 15mm or more can cause lingual perforation (Figure 3). 100% of interns were aware of the fact that direct ligations are the best method to control hemorrhage intra operatively in the mandible (Figure 4). Yet almost 50% of the students from final year and internship were not aware of embolisation of arteries to be the minimally invasive method to minimise blood loss (Figure 5). 100% of the students pursuing their internship were aware of the methods to manage hemorrhage from bony canals such as, the use of anaesthetic spray, burnishing the bone and use of bone grafting (Figure 6). Also, 100% of the students doing their internship were aware that deep ligation, direct sutures and flap adaptation to be definitive Methods to control arterial bleeding intra operatively (Figure 7). Most of the students from internship and final year were aware of the Methods such as the use of CBCT and digital palpation of anatomical landmarks prior to flap elevation to avoid arterial nicking during implant placement or other oral surgical procedures (Figure 8). 73% of students from internship were aware of the fact that securing airway to be the initial and foremost important step in controlling intra operative complications (Figure 9). 80% of students from internship were aware about the use of angiography and CT with contrast in identifying the source of hemorrhage (Figure 10).



**Figure 1: Bar chart showing the response of dental students for the question on awareness of the term iatrogenic arterial nicking. Yes is represented in blue and no in green. The X axis represents the year of study of respondents and the Y axis scale shows the total count of responses. It is evident from the graph that 100% of students from final year and internship were totally aware of it.**

What are the Causes of bleeding during implant placement in mandibular region?

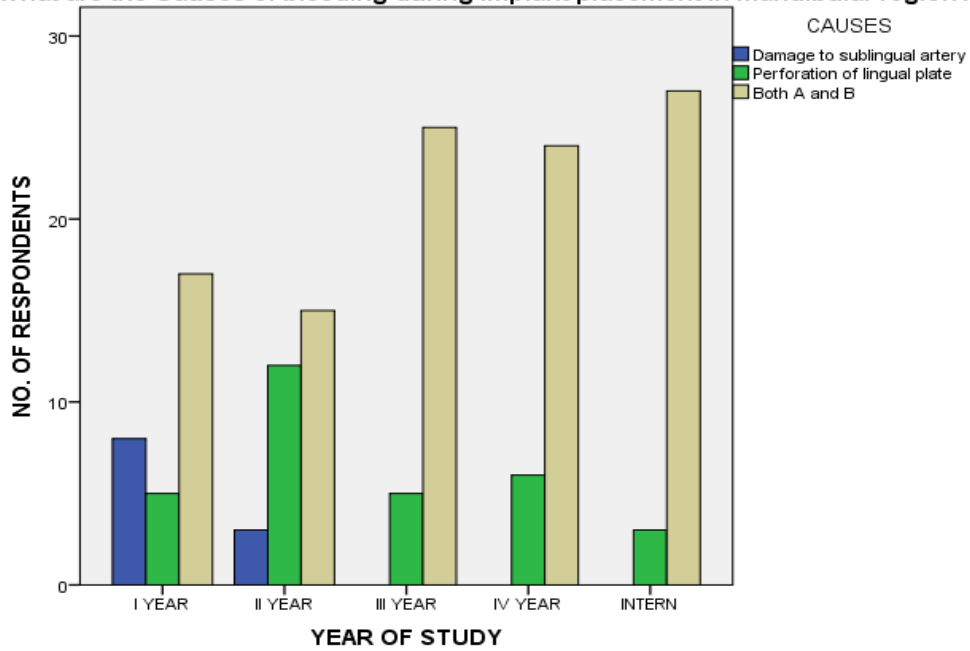


Figure 2: Bar chart showing the response of dental students for the question on causes of bleeding during implant placement in the mandibular region. Option A (damage to sublingual artery) is represented in blue, option B (perforation of lingual plate) in green and option C (both A and B) is represented in cream colour. The X axis represents the year of study of respondents and the Y axis scale shows the total count of responses. It is evident from the graph that the maximum number of students from final year (80%) and internship (90%) have answered correctly to be due to perforation of the lingual plate and Damage of sublingual artery.

What would be the Length of implant that can usually cause perforation?

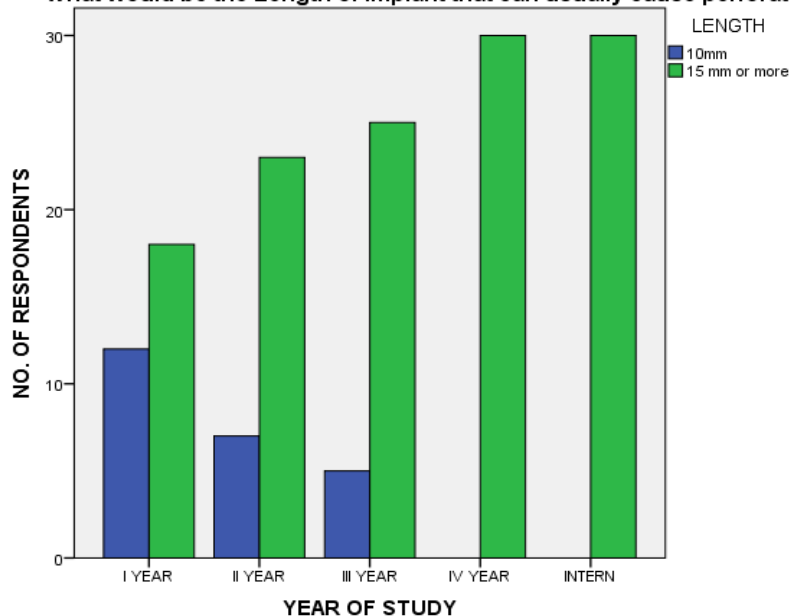
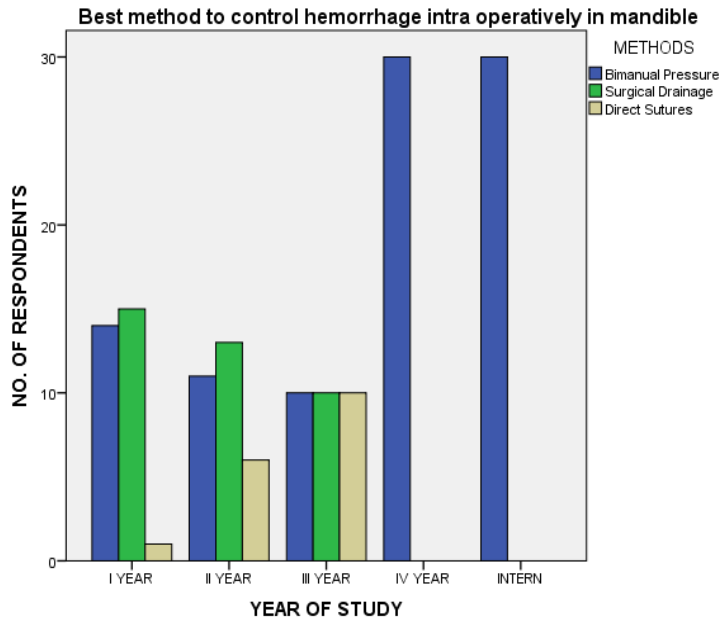
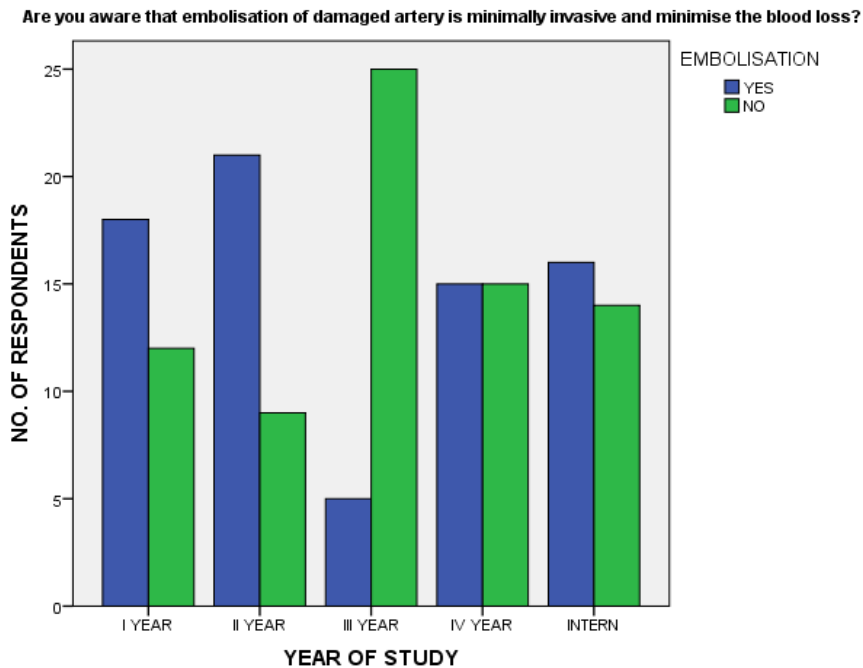


Figure 3: Bar chart showing the response of dental students for the question on the length of implant that can cause perforation of lingual canal. Option A (10mm) is represented in blue, option B (15mm or more) in green). The X axis represents the year of study of respondents and the Y axis scale shows the total count of responses. It is evident from the graph that 100% of students from internship were aware of the fact that implants of length 15mm or more can cause lingual perforation.



**Figure 4:** Bar chart showing the response of dental students for the question on intra operative management of hemorrhage in the mandible. Option A (bimanual pressure) is represented in blue, option B (surgical drainage) in green and option C (direct sutures) is represented in cream colour. The X axis represents the year of study of respondents and the Y axis scale shows the total count of responses. It is evident from the graph that 100% of interns were aware of the fact that direct ligations are the best method to control hemorrhage intra operatively in the mandible.



**Figure 5:** Bar chart showing the response of dental students for the question on awareness on embolisation to be a minimally invasive technique to minimise blood loss. Yes is represented in blue and no in green. The X axis represents the year of study of respondents and the Y axis scale shows the total count of responses. It is evident from the graph that only 50% of the students from final year and internship were aware of embolisation of arteries to be the minimally invasive method to minimise blood loss.

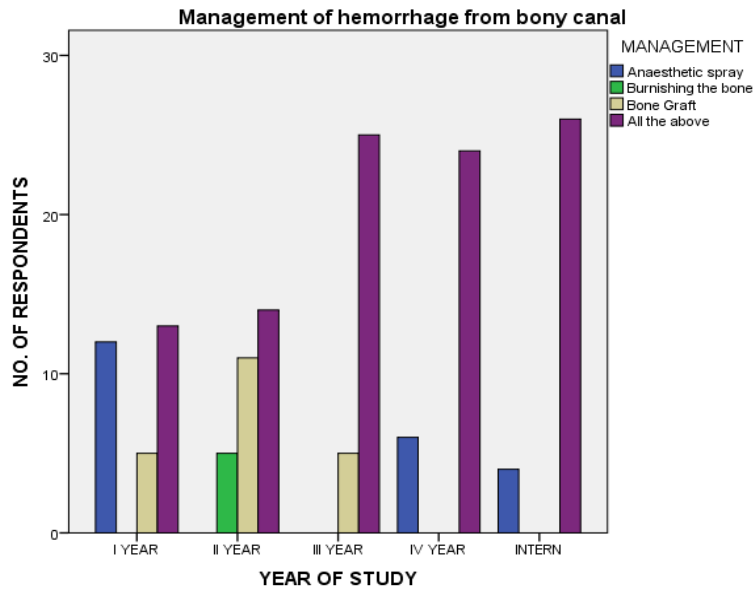


Figure 6: Bar chart showing the response of dental students for the question on management of hemorrhage from bony canal. Option A (use of anaesthetic spray) is represented in blue, option B (burnishing the bone) in green, option C (use of bone graft) is represented in cream colour and option D (all the above) is represented in purple. The X axis represents the year of study of respondents and the Y axis scale shows the total count of responses. It is evident from the graph that 100% of the students pursuing their internship were aware of the methods to manage hemorrhage from bony canals such as, the use of anaesthetic spray, burnishing the bone and use of bone grafting.

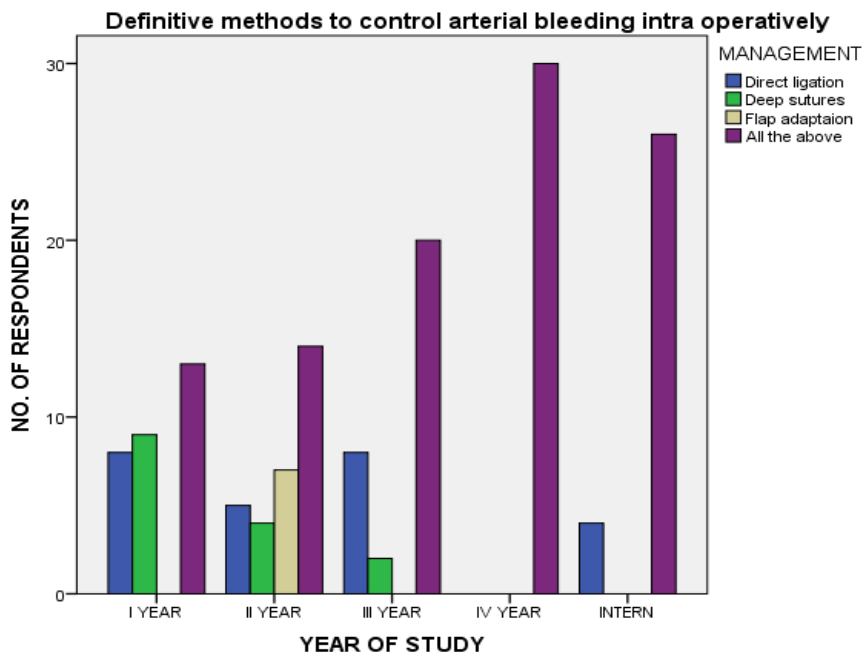
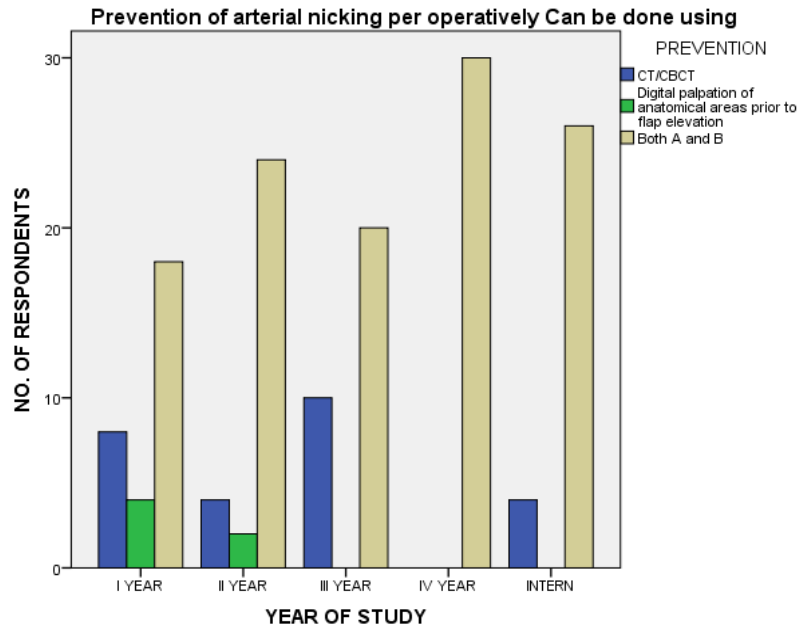
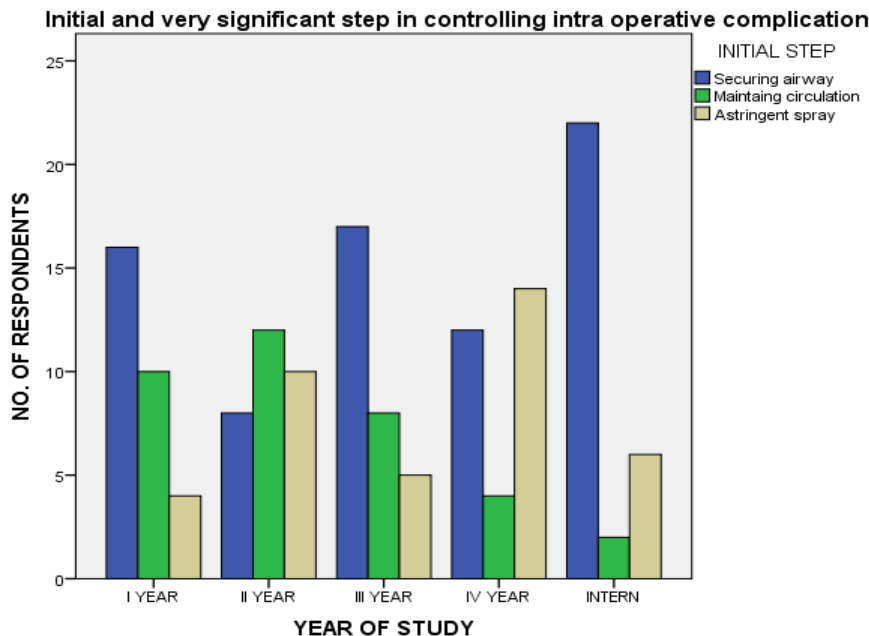


Figure 7: Bar chart showing the response of dental students for the question on definitive methods on controlling arterial bleeding intra operatively. Option A (direct ligation) is represented in blue, option B (deep sutures) in green, option C (flap adaptation) is represented in cream colour and option D (all the above) is represented in purple. The X axis represents the year of study of respondents and the Y axis scale shows the total count of responses. It is evident from the graph that 100% of the students doing their internship were aware that deep ligation, direct sutures and flap adaptation to be definitive Methods to control arterial bleeding intra operatively.

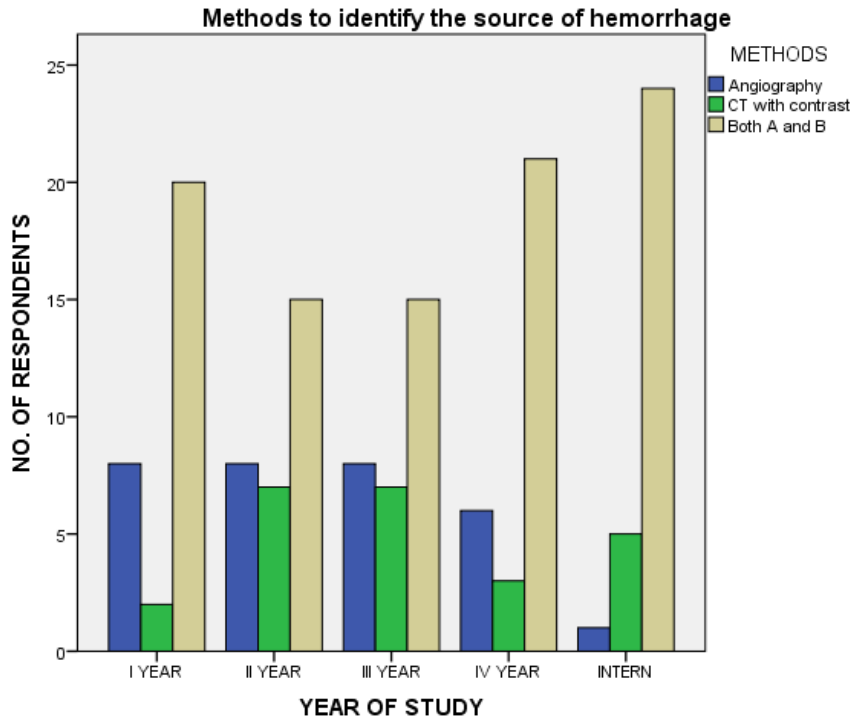


**Figure 8:** Bar chart showing the response of dental students for the question on preventive methods to avoid arterial nicking. Option A (use of CT/CBCT) is represented in blue, option B (Digital palpation) in green and option C (both A and B) is represented in cream colour. The X axis represents the year of study of respondents and the Y axis scale shows the total count of responses. It is evident from the graph that most of the students from internship and final year were aware of the Methods such as the use of CBCT and digital palpation of anatomical landmarks prior to flap elevation to avoid arterial nicking during implant placement or other oral surgical procedures



**Figure 9:** Bar chart showing the response of dental students for the question on initial step in controlling intra operative complication. Option A (securing the airway) is represented in blue, option B (maintaining circulation) in green and option C (use of astringent spray) is represented in cream colour. The X axis represents the year of study of respondents and the Y axis scale shows the total count of responses. It is evident from the graph that 73% of students from internship were aware of the fact that securing airway to be the initial and foremost important step in controlling intra operative complications.





**Figure 10: Bar chart showing the response of dental students for the question on methods to identify the source of hemorrhage. Option A (angiography) is represented in blue, option B (use of CT with contrast) in green and option C (both A and B) is represented in cream colour. The X axis represents the year of study of respondents and the Y axis scale shows the total count of responses. It is evident from the graph that 80% of students from internship were aware about the use of angiography and CT with contrast in identifying the source of hemorrhage.**

In the current study, for all the questions asked to analyse the knowledge and awareness on the management of iatrogenic arterial nicking during surgical procedures, dental undergraduate students pursuing their final year and internship had a better knowledge and awareness when compared to the students from other subsequent years of study.

The lingual nerve and inferior alveolar nerve injuries are similar and that lingual nerve injuries in association with lingual access third molar surgery are mainly temporary, with 88% of lingual nerve injuries resolving in the first 10 weeks post surgery. In contrast, the IAN is at more risk from a variety of dental procedures and the IAN is contained within a bony canal, predisposing it to ischaemic trauma and subsequent injury.(39) This may also result in a higher incidence of permanent damage for inferior alveolar nerve injuries. The Causes of inferior alveolar nerve injury include: Local anaesthetic injections; Third molar surgery; Implants; Endodontics; Ablative surgery; Trauma; and Orthognathic surgery. The inferior alveolar nerve (IAN) neuropathy related to third molar surgery or inferior dental block injections (IDBs) is usually temporary but can persist and become permanent (at 3 months).(40) There are rare reports of resolution of implant-related IAN neuropathies over 4 years, but these do not comply with normal reports of peripheral sensory nerve injuries. Many authors recommend referral of injuries after 6 months, but this may be too late for many other peripheral sensory nerve injuries. We now understand that, after 3 months, permanent central and peripheral changes occur within the nervous system, subsequent to injury, that are unlikely to respond to surgical intervention. (41)

The management will depend upon the mechanism and the duration of the nerve injury. Many injuries have limited benefit from surgical intervention and should be managed symptomatically using medication or counselling. Immediate intervention is required for endodontic, implant and third molar-related nerve injuries and immediate referral is suggested for all cases.

Limitations of this study include Geographic limitation as predominantly South Indian population of dentists were only considered, and was a Unicentric study with few Incomplete and unclear data. The Future scope of this study will yield a better and more accurate result when different ethnic populations are considered.

## CONCLUSIONS

Within the limitations of the current study, it can be concluded that the majority of dental undergraduate students are aware of different methods of presentation and management of iatrogenic arterial nicking during

dental surgical procedures. In the present study the knowledge on the methods of management such as mobilisation, deep sutures, burnishing of bone, use of bone grafting was lacking among first to third year students when compared to students pursuing their final year and internship . Since the protocol and techniques for dental surgery differ, students tend to get misguided. Further CDE programmes can be conducted to raise awareness among dental students about the different methods of management and prevention of iatrogenic arterial nicking during dental oral procedures.

#### ACKNOWLEDGEMENT

The authors would like to acknowledge the help and support rendered by the Department of prosthodontics, Saveetha Dental College and Hospitals, Saveetha Institute of Medical and Technical Sciences, Saveetha University, Chennai.

#### FUNDING

The present study is funded by

- Saveetha Institute of Medical and Technical Sciences
- Saveetha Dental College and Hospitals
- Saveetha University
- Akshaya Associates Private Limited, Chennai.

#### CONFLICT OF INTEREST

Nil.

#### REFERENCES

1. Martin K, Nathwani S. The frontline management of postoperative haemorrhage following dentoalveolar surgery: an audit [Internet]. Vol. 55, British Journal of Oral and Maxillofacial Surgery. 2017. p. e112-3. Available from: <http://dx.doi.org/10.1016/j.bjoms.2017.08.082>
2. Zadik Y. Oral trauma and dental emergency management recommendations of first-aid textbooks and manuals. Dent Traumatol. 2007 Oct;23(5):304-6.
3. Singh K. Hematoma - A Complication of Posterior Superior Alveolar Nerve Block [Internet]. Journal of Dental Problems and Solutions. 2015. p. 015-6. Available from: <http://dx.doi.org/10.17352/2394-8418.000009>
4. Peterson LJ. Contemporary Oral and Maxillofacial Surgery. Mosby Elsevier Health Science; 1993. 799 p.
5. Bano AM, Ganapathy D, Pandurangan KK. Inferior Alveolar Nerve Injury during Implant Placement -A Review. Annals of RSCB. 2021 May 12;15592-603.
6. Malamed SF. Handbook of Local Anesthesia - E-Book. Elsevier Health Sciences; 2014. 432 p.
7. Laskin DM. Oral and Maxillofacial Surgery. 1980. 736 p.
8. Caissie R, Goulet J, Fortin M, Morielli D. Iatrogenic paresthesia in the third division of the trigeminal nerve: 12 years of clinical experience. J Can Dent Assoc. 2005 Mar;71(3):185-90.
9. Miloro M. Trigeminal Nerve Injuries. Springer Science & Business Media; 2013. 366 p.
10. Kamlesh R, Ganapathy D, Tulsani MG, Others. EFFECTIVENESS OF GOW-GATES AND INFERIOR ALVEOLAR NERVE BLOCKS IN INDUCING ANAESTHESIA IN PATIENTS UNDERGOING FULL MOUTH REHABILITATION. PalArch's Journal of Archaeology of Egypt/Egyptology. 2020;17(7):1408-13.
11. Ziccardi VB, Assael LA. Mechanisms of Trigeminal Nerve Injuries [Internet]. Vol. 9, Atlas of the Oral and Maxillofacial Surgery Clinics. 2001. p. 1-11. Available from: [http://dx.doi.org/10.1016/s1061-3315\(18\)30013-1](http://dx.doi.org/10.1016/s1061-3315(18)30013-1)
12. Renton T. Prevention of Iatrogenic Inferior Alveolar Nerve Injuries in Relation to Dental Procedures [Internet]. Vol. 37, Dental Update. 2010. p. 350-63. Available from: <http://dx.doi.org/10.12968/denu.2010.37.6.350>
13. Arx TV, Von Arx T, Häfliger J, Chappuis V. Neurosensory disturbances following bone harvesting in the symphysis: a prospective clinical study [Internet]. Vol. 16, Clinical Oral Implants Research. 2005. p. 432-9. Available from: <http://dx.doi.org/10.1111/j.1600-0501.2005.01138.x>
14. Feifel H, Riediger D, Gustorf-Aeckerle R. High resolution computed tomography of the inferior alveolar and lingual nerves [Internet]. Vol. 36, Neuroradiology. 1994. p. 236-8. Available from: <http://dx.doi.org/10.1007/bf00588141>

15. Harris D, Buser D, Dula K, Gröndahl K, Harris D, Jacobs R, et al. E.A.O. Guidelines for the use of Diagnostic Imaging in Implant Dentistry [Internet]. Vol. 13, Clinical Oral Implants Research. 2002. p. 566–70. Available from: <http://dx.doi.org/10.1034/j.1600-0501.2002.130518.x>
16. Greenstein G, Tarnow D. The mental foramen and nerve: clinical and anatomical factors related to dental implant placement: a literature review. *J Periodontol.* 2006 Dec;77(12):1933–43.
17. Shavit I, Juodzbaly G. Inferior Alveolar Nerve Injuries Following Implant Placement - Importance of Early Diagnosis and Treatment: a Systematic Review [Internet]. Vol. 5, Journal of Oral and Maxillofacial Research. 2014. Available from: <http://dx.doi.org/10.5037/jomr.2014.5402>
18. Duraisamy R, Krishnan CS, Ramasubramanian H, Sampathkumar J, Mariappan S, Navarasampatti Sivaprakasam A. Compatibility of Nonoriginal Abutments With Implants: Evaluation of Microgap at the Implant-Abutment Interface, With Original and Nonoriginal Abutments. *Implant Dent.* 2019 Jun;28(3):289–95.
19. Sivasamy R, Venugopal P, Mosquera E. Synthesis of Gd<sub>2</sub>O<sub>3</sub>/CdO composite by sol-gel method: Structural, morphological, optical, electrochemical and magnetic studies. *Vacuum.* 2020 May 1;175:109255.
20. Arvind P TR, Jain RK. Skeletally anchored forsus fatigue resistant device for correction of Class II malocclusions-A systematic review and meta-analysis. *Orthod Craniofac Res.* 2021 Feb;24(1):52–61.
21. Venugopal A, Vaid N, Bowman SJ. Outstanding, yet redundant? After all, you may be another Choluteca Bridge! *Semin Orthod.* 2021 Mar 1;27(1):53–6.
22. Dhanraj G, Rajeshkumar S. Anticariogenic Effect of Selenium Nanoparticles Synthesized Using Brassica oleracea. *J Nanomater* [Internet]. 2021 Jul 10 [cited 2021 Aug 27];2021. Available from: <https://www.hindawi.com/journals/jnm/2021/8115585/>
23. Neelakantan P, Grotra D, Sharma S. Retreatability of 2 mineral trioxide aggregate-based root canal sealers: a cone-beam computed tomography analysis. *J Endod.* 2013 Jul;39(7):893–6.
24. Aldhuwayhi S, Mallineni SK, Sakhamuri S, Thakare AA, Mallineni S, Sajja R, et al. Covid-19 Knowledge and Perceptions Among Dental Specialists: A Cross-Sectional Online Questionnaire Survey. *Risk Manag Healthc Policy.* 2021 Jul 7;14:2851–61.
25. Sheriff KAH, Ahmed Hilal Sheriff K, Santhanam A. Knowledge and Awareness towards Oral Biopsy among Students of Saveetha Dental College [Internet]. Vol. 11, Research Journal of Pharmacy and Technology. 2018. p. 543. Available from: <http://dx.doi.org/10.5958/0974-360x.2018.00101.4>
26. Markov A, Thangavelu L, Aravindhan S, Zekiy AO, Jarahian M, Chartrand MS, et al. Mesenchymal stem/stromal cells as a valuable source for the treatment of immune-mediated disorders. *Stem Cell Res Ther.* 2021 Mar 18;12(1):192.
27. Jayaraj G, Ramani P, Herald J. Sherlin, Premkumar P, Anuja N. Inter-observer agreement in grading oral epithelial dysplasia - A systematic review [Internet]. Vol. 27, Journal of Oral and Maxillofacial Surgery, Medicine, and Pathology. 2015. p. 112–6. Available from: <http://dx.doi.org/10.1016/j.ajoms.2014.01.006>
28. Paramasivam A, Priyadharsini JV, Raghunandhakumar S, Elumalai P. A novel COVID-19 and its effects on cardiovascular disease. *Hypertens Res.* 2020 Jul;43(7):729–30.
29. Li Z, Veeraraghavan VP, Mohan SK, Bolla SR, Lakshmanan H, Kumaran S, et al. Apoptotic induction and anti-metastatic activity of eugenol encapsulated chitosan nanopolymer on rat glioma C6 cells via alleviating the MMP signaling pathway [Internet]. Vol. 203, Journal of Photochemistry and Photobiology B: Biology. 2020. p. 111773. Available from: <http://dx.doi.org/10.1016/j.jphotobiol.2019.111773>
30. Gan H, Zhang Y, Zhou Q, Zheng L, Xie X, Veeraraghavan VP, et al. Zingerone induced caspase-dependent apoptosis in MCF-7 cells and prevents 7,12-dimethylbenz(a)anthracene-induced mammary carcinogenesis in experimental rats. *J Biochem Mol Toxicol.* 2019 Oct;33(10):e22387.
31. Dua K, Wadhwa R, Singhvi G, Rapalli V, Shukla SD, Shastri MD, et al. The potential of siRNA based drug delivery in respiratory disorders: Recent advances and progress. *Drug Dev Res.* 2019 Sep;80(6):714–30.
32. Mohan M, Jagannathan N. Oral field cancerization: an update on current concepts. *Oncol Rev.* 2014 Mar 17;8(1):244.
33. Agarwal S, Ashok V, Maiti S, Agarwal V. Dentists' Preference toward Fixed Versus Removable

- Implant Prosthesis on Edentulous Jaws to Improve Quality of Life. *J Long Term Eff Med Implants*. 2022;33(1):83–9.
34. Kushali R, Maiti S, Girija SAS, Jessy P. Evaluation of Microbial Leakage at Implant Abutment Interfact for Different Implant Systems: An In Vitro Study. *J Long Term Eff Med Implants*. 2022;32(2):87–93.
  35. Aparna J, Maiti S, Jessy P. Polyether ether ketone - As an alternative biomaterial for Metal Richmond crown-3-dimensional finite element analysis. *J Conserv Dent*. 2021 Nov-Dec;24(6):553–7.
  36. Ponnanna AA, Maiti S, Rai N, Jessy P. Three-dimensional-Printed Malo Bridge: Digital Fixed Prosthesis for the Partially Edentulous Maxilla. *Contemp Clin Dent*. 2021 Dec 21;12(4):451–3.
  37. Venugopalan S, R S, N T, Maiti S. An Analysis of Implant Prosthesis and Its Dynamic Occlusal Contacts. *J Long Term Eff Med Implants*. 2022;33(1):1–7.
  38. Merchant A, Ganapathy DM, Maiti S. Effectiveness of local and topical anesthesia during gingival retraction [Internet]. Vol. 25, *Brazilian Dental Science*. 2022. p. e2591. Available from: <http://dx.doi.org/10.4322/bds.2022.e2591>
  39. Elian N, Mitsias M, Eskow R, Jalbout ZN, Cho SC, Froum S, et al. Unexpected Return of Sensation Following 4.5 Years of Paresthesia: Case Report [Internet]. Vol. 14, *Implant Dentistry*. 2005. p. 364–70. Available from: <http://dx.doi.org/10.1097/01.id.0000190252.60779.ae>
  40. Robinson PP, Smith KG. How clinical research changed the habit of a lifetime [Internet]. Vol. 183, *British Dental Journal*. 1997. p. 238–238. Available from: <http://dx.doi.org/10.1038/sj.bdj.4809474>
  41. Kraut RA, Chahal O. Management of patients with trigeminal nerve injuries after mandibular implant placement [Internet]. Vol. 133, *The Journal of the American Dental Association*. 2002. p. 1351–4. Available from: <http://dx.doi.org/10.14219/jada.archive.2002.0050>